

Case Report on Epidermalization of Cervix: A Gynaecopathological Conundrum

CHAITANYA INDRANI¹, ANJALI ANTONY², ASTHA AGRAWAL³

(CC) BY-NC-ND

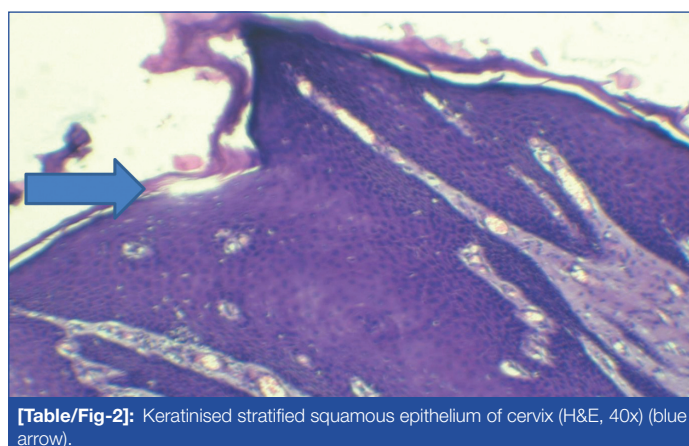
ABSTRACT

The cervix could exhibit changes like adenosis, squamous hyperplasia, hyperkeratosis and parakeratosis which are usually reactionary changes. This is generally found in cases secondary to uterine prolapse where there is scope in the cervix for continuous irritation and epidermoid metaplasia. A young woman (36-year-old Para 3 Living 3) came with complaints of mass per vagina and heavy menstrual bleeding. On examination, she had cervical elongation and histopathology after hysterectomy showed epidermalisation of the cervix. This unfamiliar finding raises the question of ectodermal-type structures in tissue that originated from mesoderm or endoderm. Considering the primary cause that expose the cervix and vagina, like uterine prolapse or cervical elongation, this phenomenon could be a metaplastic change more than a developmental oddity.

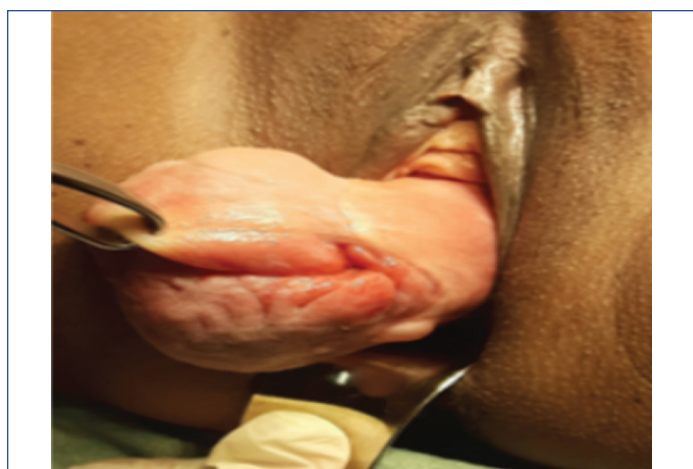Keywords: Ectoderm development, Embryology hyperplasia, Epidermalisation

CASE REPORT

A 36-year-old woman Para 3 Living 3, came with complaints of mass per vagina since one year gradually increasing in size and she also had lower abdominal pain, (dull aching, type aggravated on heavy work and heavy menstrual bleeding since three months. Her haemoglobin was 8 g/dL. On gross examination, the external surface of the cervix appeared hypertrophied and elongated, with evidence of epidermalisation was seen [Table/Fig-1]. She was explained the condition and was not willing for conservative options. Hence, proceeded with a total abdominal hysterectomy and the specimen was sent for histopathology {Haematoxylin and Eosin (H&E) staining}. Microscopy showed ectocervix lining showed keratinised stratified squamous epithelium and endocervix had columnar epithelium [Table/Fig-2]. Patient had uneventful recovery and reported no further complaints on follow-up visits.



[Table/Fig-2]: Keratinised stratified squamous epithelium of cervix (H&E, 40x) (blue arrow).



[Table/Fig-1]: Preoperative image of the elongated cervix.

DISCUSSION

Reactionary changes such as adenosis, squamous hyperplasia, hyperkeratosis and parakeratosis in the cervix are well known. These changes are associated with cases secondary to uterine prolapse, where there is scope in the cervix for persistent friction or irritation and can undergo epidermoid metaplasia [1,2]. What makes this finding intriguing is that both the cervix and the upper

third of the vagina are embryologically derived from the Müllerian duct. The ectocervix is lined by non keratinised stratified squamous epithelium, while the lining epithelium of skin is keratinised stratified squamous epithelium. The presence of the epidermal lining and skin appendages, like the sebaceous and sweat glands, as well as hair follicles in the cervix and vagina, has been documented [3]. One possible explanation for this phenomenon could be the repeated erosions, with subsequent healing and replacement by squamous epithelium at the squamocolumnar junction of the cervix. This epidermis-like transformation of this sort also called prosoplasia, is mostly seen in uterine prolapse or cervical elongation with hypertrophy, as seen in the present case [4]. Another explanation by certain authors is true heterotopia or mislaid embryonic tissue. The Müllerian duct meets the Müllerian tubercle, resulting in the early urogenital sinus. The lining of the urogenital sinus is later substituted by squamous epithelium, resulting in the squamocolumnar junction and transformation zone of the cervix [5]. Hence, the vulva, with an epidermal lining and accommodating skin appendages and the cervix may share similar origins [4,5]. Brady A and mccluggage WG describe a case series of 11 cases about the ectodermal structures in the cervix out of which only three patients were less than 45 years of age [6]. Given the limited number of documented cases of this phenomenon, the authors present few cases of a young patient to contribute to the existing literature [Table/Fig-3] [4,6].

S. No.	Authors name	Age/gender	Condition	Histopathological findings
1	Ionescu DN et al., [4]	44/F	Uterovaginal prolapse	Keratinised squamous epithelium of cervix hyperkeratosis sebaceous glands
2	Brady A and McCluggage WG [6]	43/F	Uterine fibroid with cervical elongation	Hyperkeratosis sebaceous glands melanin pigments
		43/F	Borderline cervical smear on routine screening	Sebaceous glands and hair follicle-like structures
		33/F	Moderate dyskaryosis on smear on routine screening	Sebaceous glands

[Table/Fig-3]: Summary of few similar cases published in literature [4,6].

CONCLUSION(S)

This unfamiliar finding raises the question of ectodermal type structures in tissue that originated from mesoderm or endoderm. Considering the primary cause that exposes the cervix and vagina, like uterine prolapse or cervical elongation, this phenomenon could be a metaplastic change more than a developmental oddity.

REFERENCES

- [1] Watson AA, Cochran AJ. Sebaceous glands of the cervix uteri and buccal mucosa. J Pathol. 1969;98:87Y9.
- [2] Rosa M, Moore G. Epidermalization of cervix and vagina: An unsolved dilemma. J Low Genit Tract Dis. 2008;12(3):217-19.
- [3] Robledo MC, Vazquez JJ, Contreras-Mejuto F, Lopez-Garcia G. Sebaceous glands and hair follicles in the cervix uteri. Histopathology. 1992;21(3):278-80.
- [4] Ionescu DN, Mohan D, Carter G, Dabbs DJ. Epidermoid metaplasia of the cervix. Arch Pathol Lab Med. 2004;128(9):1052-53.
- [5] Ehrmann RL. Sebaceous metaplasia of the human cervix. Am J Obstet Gynecol. 1969;105(8):1284-86.
- [6] Brady A, McCluggage WG. Ectodermal structures within the uterine cervix and vagina: Report of a series of cases. Int J Gynecol Pathol. 2013;32(6):602-05.

PARTICULARS OF CONTRIBUTORS:

1. Associate Professor, Department of Obstetrics and Gynaecology, MVJ Medical College, Bengaluru, Karnataka, India.
2. Assistant Professor, Department of Obstetrics and Gynaecology, MVJ Medical College, Bengaluru, Karnataka, India.
3. Postgraduate, Department of Obstetrics and Gynaecology, MVJ Medical College, Bengaluru, Karnataka, India.

NAME, ADDRESS, E-MAIL ID OF THE CORRESPONDING AUTHOR:

Dr. Chaitanya Indrani,
Associate Professor, Department of Obstetrics and Gynaecology, MVJ Medical College
and Research Hospital, Hoskote, Bengaluru-562114, Karnataka, India.
E-mail: drpcindrani1537@gmail.com

PLAGIARISM CHECKING METHODS: [Jain H et al.]

- Plagiarism X-checker: Nov 14, 2024
- Manual Googling: Feb 15, 2025
- iThenticate Software: Feb 18, 2025 (4%)

ETYMOLOGY: Author Origin

EMENDATIONS: 6

AUTHOR DECLARATION:

- Financial or Other Competing Interests: None
- Was informed consent obtained from the subjects involved in the study? Yes
- For any images presented appropriate consent has been obtained from the subjects. Yes

Date of Submission: **Nov 12, 2024**

Date of Peer Review: **Jan 06, 2025**

Date of Acceptance: **Feb 20, 2025**

Date of Publishing: **Jun 01, 2025**